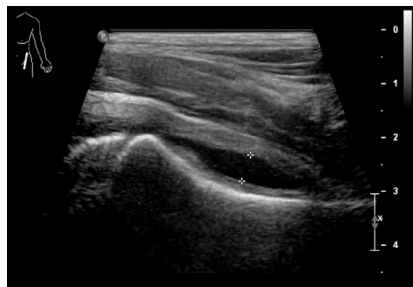
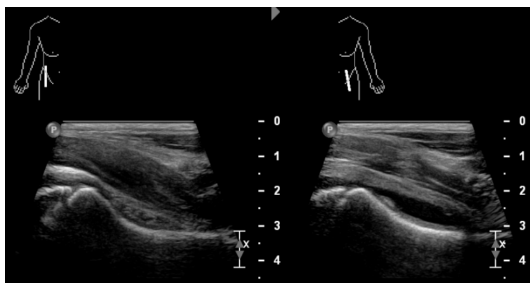
Recommended Standard Views for Hip USG Screening for Effusion

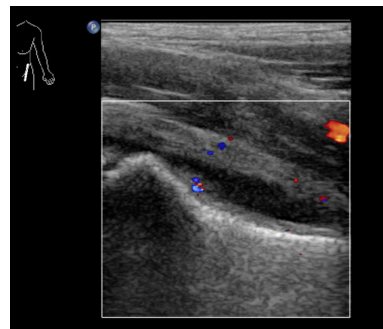
1. Ant. Hip recess LS
→ Any effusion?



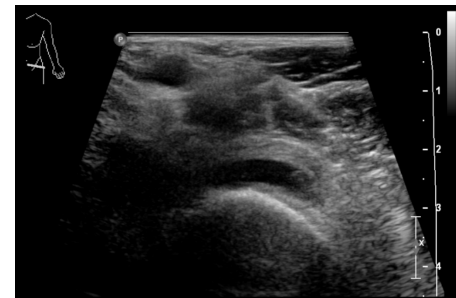2. Compare to asymptomatic side



3. Color Doppler



4. Take TS image if effusion +ve



TIP: Center on anterior hip recess

Report
(1) any hip effusion
(2) any synovitis