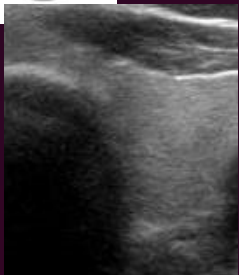
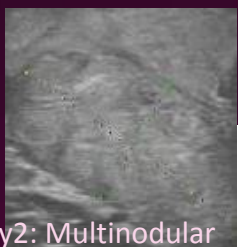

U1

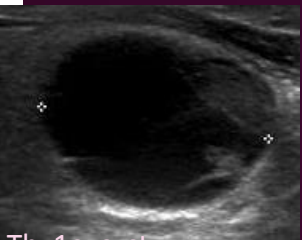


Normal. No FNA

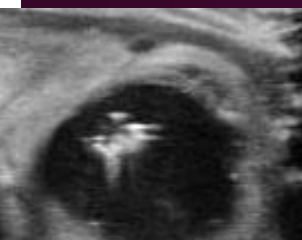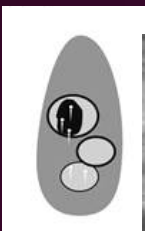


Thy2: Multinodular goitre

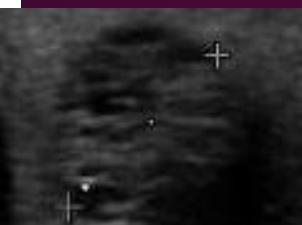

U2



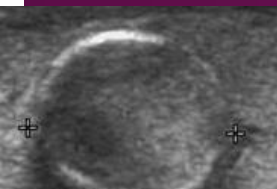
Thy1c: cyst



Ring down artefact.  
Thy2c: colloid cyst

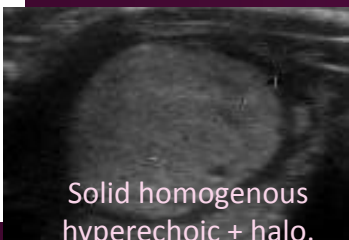



Microcystic / Spongiform nodule. No FNA

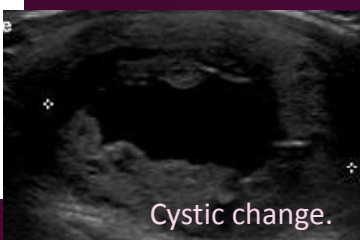


Peripheral eggshell calcification.  
Thy1, repeated Thy2

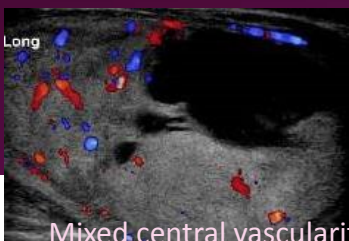
U3



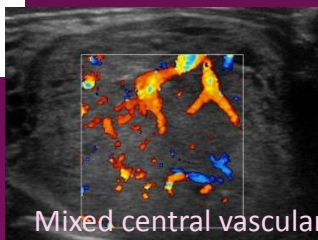
Solid homogenous hyperechoic + halo.  
Thy3a. Hemithyroidectomy: papillary thyroid carcinoma



Cystic change.  
Thy3a. Repeat: Thy2

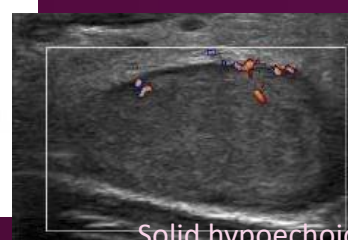

Mixed central vascularity.  
Thy3F. Hemithyroidectomy: Follicular adenoma

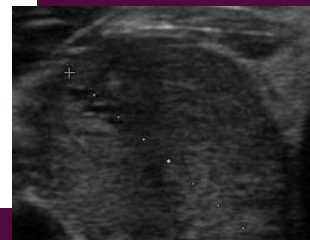


Mixed central vascularity. Thy4.  
Papillary thyroid carcinoma

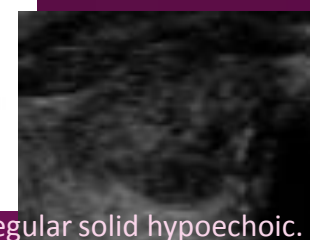
U4



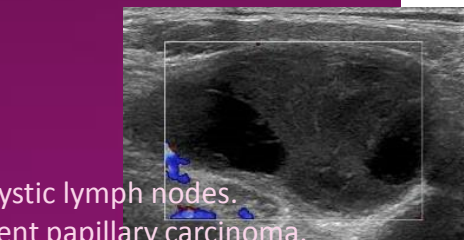

Solid hypoechoic.  
Thy3a. Follicular adenoma



Solid hypoechoic. Thy3F.  
Hemithyroidectomy: Follicular tumour of uncertain malignant potential.

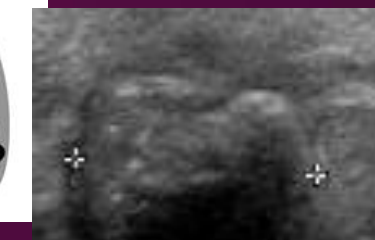

Irregular solid hypoechoic.  
Papillary thyroid carcinoma

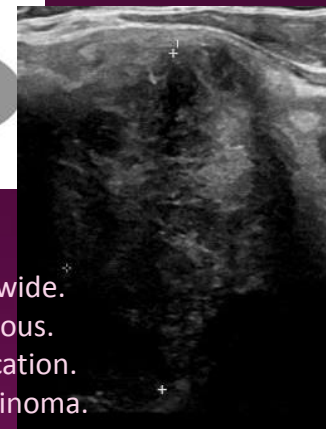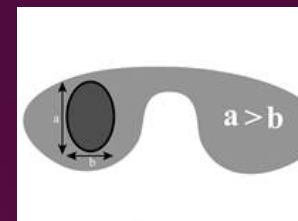


Cystic lymph nodes.  
Recurrent papillary carcinoma.

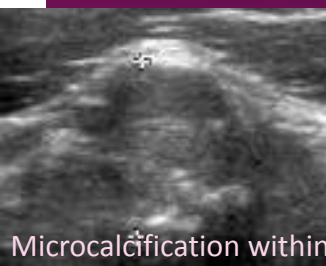
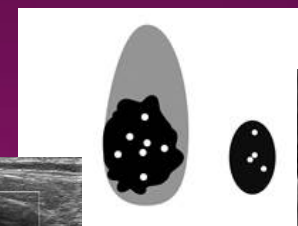
U5



Solid hypoechoic, irregular margin, microcalcification. Papillary Carcinoma



Taller than wide.  
Heterogenous.  
Microcalcification.  
Papillary carcinoma.



Microcalcification within level IV cervical lymph node.  
Medullary carcinoma

Pictorial review of thyroid nodules according to the British Thyroid Association classification with corresponding cytological and histological outcomes.